

Clinical Guideline for Acquired Facial Nerve Palsy in Children (Bell's Palsy)

For Use in:	Jenny Lind Children's Hospital
By:	Medical and Nursing Staff
For:	Children with acquired Facial Nerve Palsy
Division responsible for document:	Women and Children Services
Key words:	Facial Nerve Palsy, Bell's Palsy
Name of document author:	Dr. Vivek Kalra
Job Title of document author:	ST7 Paediatrics
Name of document author's Line Manager:	Dr. Ruchi Arora
Job title of author's Line Manager:	Consultant Paediatrics with expertise in Paediatric Epilepsy and Neurology
Supported by:	Dr. Bina Mukhtyar
Assessed and approved by the:	Clinical Guidelines Assessment Panel (CGAP) If approved by committee or Governance Lead Chair's Action; tick here ✓
Date of approval:	24/04/2020
Ratified by or reported as approved to (if applicable):	Clinical Safety and Effectiveness Sub-board.
To be reviewed before: This document remains current after this date but will be under review	24/04/2023
To be reviewed by:	Author
Reference and / or Trust Docs ID No:	14349
Version No:	1.2
Compliance links:	None
If Yes - does the strategy/policy deviate from the recommendations of NICE? If so why?	N/A

This guideline has been approved by the Trust's Clinical Guidelines Assessment Panel as an aid to the diagnosis and management of relevant patients and clinical circumstances. Not every patient or situation fits neatly into a standard guideline scenario and the guideline must be interpreted and applied in practice in the light of prevailing clinical circumstances, the diagnostic and treatment options available and the professional judgement, knowledge and expertise of relevant clinicians. It is advised that the rationale for any departure from relevant guidance should be documented in the patient's case notes.

The Trust's guidelines are made publicly available as part of the collective endeavour to continuously improve the quality of healthcare through sharing medical experience and knowledge. The Trust accepts no responsibility for any misunderstanding or misapplication of this document.

Clinical Guideline for Acquired Facial Nerve Palsy in Children (Bell's Palsy)

Version and Document Control:

Version Number	Date of Update	Change Description	Author
1.2	24/04/2020	No clinical changes	Dr Vivek Kaira

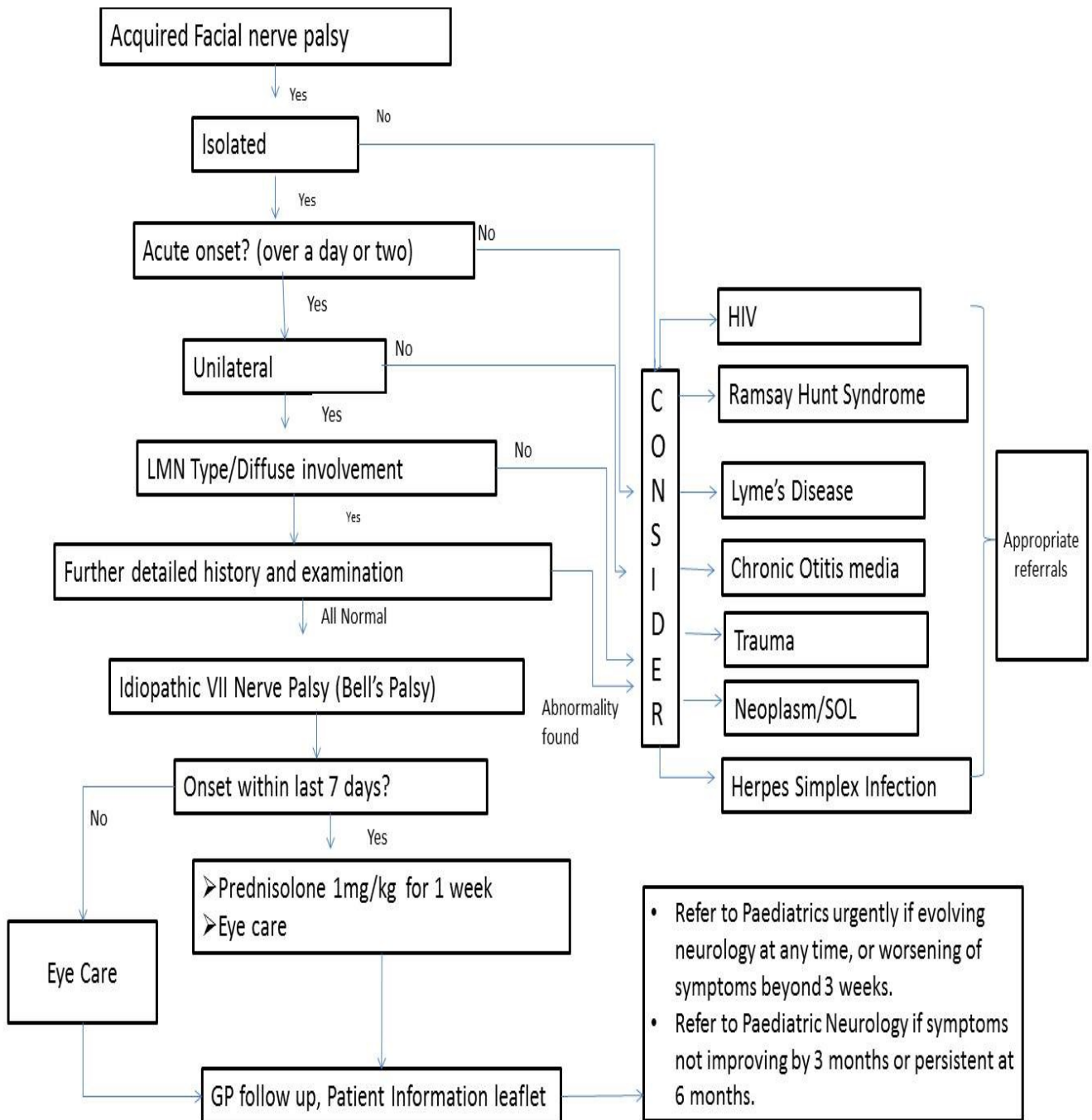
This is a Controlled Document

Printed copies of this document may not be up to date. Please check the hospital intranet for the latest version and destroy all previous versions.

Definitions of Terms Used / Glossary	
FNP	Facial Nerve Palsy
RFNP	Recurrent Facial Nerve Palsy
VZV	Varicella Zoster Virus
LMN	Lower Motor Neuron
HIV	Human Immunodeficiency Virus
SOL	Space Occupying Lesion
NCV	Nerve Conduction Velocity
FBC	Full Blood Count

Clinical Guideline for Acquired Facial Nerve Palsy in Children (Bell's Palsy)

Quick reference



Quick Links: [Corticosteroids](#), [Eye care](#), [Follow up](#), [Patient Information Leaflet](#)

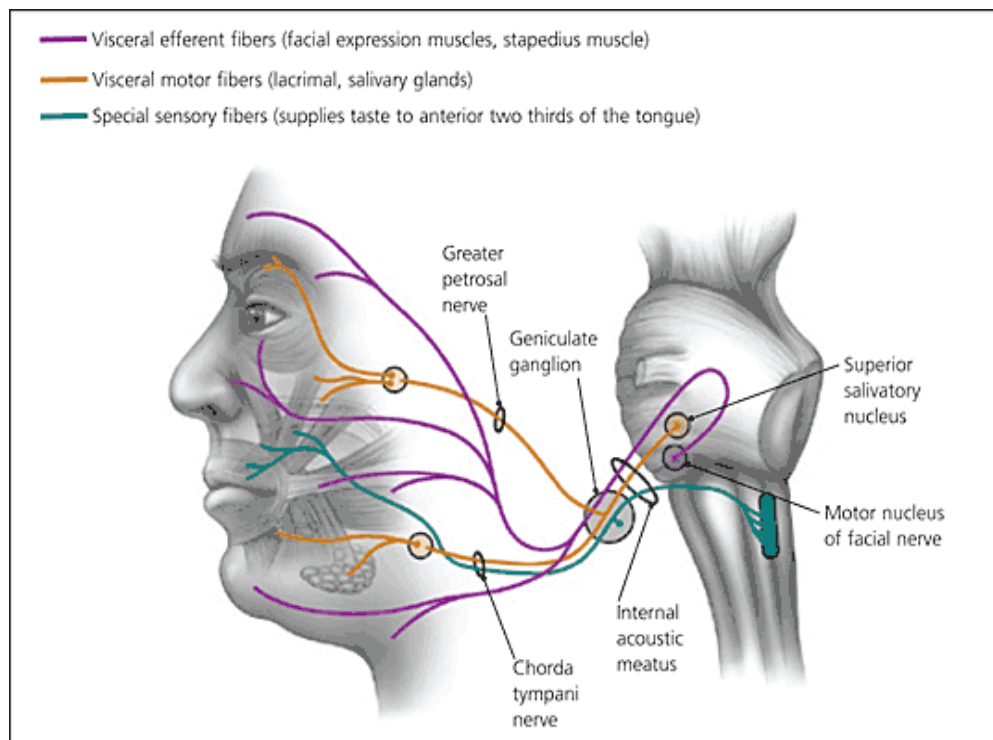
Clinical Guideline for Acquired Facial Nerve Palsy in Children (Bell's Palsy)

Objectives

- To be able to identify the cases of Idiopathic Facial Nerve Palsy.
- To be able to differentiate it from other causes of Facial Nerve Palsy.
- To deliver a structured and up to date care for children with idiopathic Facial Nerve Palsy.

Rationale

- Bell palsy is an acute, idiopathic unilateral lower motor neuron facial nerve palsy which is not associated with other cranial neuropathies or brainstem dysfunction.
- In children, Bell's palsy has an estimated incidence of about 6.1 cases per year per 100,000 in those aged between 1 and 15 years [1.2]. It is believed that it can be caused by viruses such as Herpes simplex 1.
- About 70-90% of Bell's palsy has a favourable prognosis with spontaneous resolution within 3 months, without sequelae.
- However, other causes of acquired facial nerve palsy may signify a serious underlying cause needing prompt action. Hence it is important to be able to differentiate them from cases of Bell's palsy.
- The paralysis severity at onset can influence the degree of recovery: a severe paralysis hardly obtains a complete recovery of nerve function [3-6].



Clinical Guideline for Acquired Facial Nerve Palsy in Children (Bell's Palsy)

Causes

*Idiopathic – Bell's Palsy.

*Infective

- Herpes virus type 1.
- Herpes zoster (Ramsay – Hunt syndrome).
- Cytomegalovirus, Adenovirus.
- Rubella.
- Mumps.
- Epstein-Barr virus.
- Human immunodeficiency virus.
- Otitis media or cholesteotoma.
- *Haemophilus influenza*.
- Tuberculosis.
- *Mycoplasma pneumoniae*.
- Lyme disease.

Trauma – e.g base of skull fracture.

Neurological

- Guillain Barré syndrome.
- Multiple sclerosis.
- Mononeuropathy – e.g due to sarcoidosis.

Neoplastic [7, 8]

- Posterior fossa tumours.
- Parotid gland tumours.
- Leukemia.
- Other tumors.

Hypertension

Inflammatory:[7]

Henoch-Schönlein purpura.
Kawasaki syndrome.

Clinical Guideline for Acquired Facial Nerve Palsy in Children (Bell's Palsy)

(*These are the most common causes in children)

History – Red Flags suggestive of other causes of Facial Nerve Paralysis

History and examination should ensure that the facial nerve is the only cranial nerve involved and there are no other neurological symptoms

There are a few areas of the history which should be explored, in particular ask about:

- Onset gradual over >2 weeks – May suggest mass lesion.
- Forehead not involved - Suggests central nervous system cause (supranuclear lesion).
- Bilateral involvement - Suggests Polyneuropathy.
- Fever - Consider infectious cause such as Otitis Media.
- Rash - Vesicular rash (Herpes Zoster), Erythema Migrans (Lyme Disease).
- Ear pain – prominent feature of Herpes Zoster infection.

Clinical signs and examination:

Typical findings include:

- The upper and lower portions of the face are paretic.
- Weakness of the muscles of facial expression and eye closure.
- Loss of facial creases and nasolabial fold.
- The corner of the mouth droops.
- Patients are unable to close the eye on the affected side, decreased tear production which can cause damage to the conjunctiva and cornea.

Some important points:

1. It is important to differentiate between an upper and lower motor neuron lesion on clinical examination - in a lower motor neuron lesion the patient will be unable to wrinkle their forehead in addition to the other features listed above.
2. In about 50% of cases taste on the anterior 2/3rds of the tongue is lost on the affected side.
3. Hyperacusis (uncommon) may be present.
4. Ensure that rest of neurology is normal.
5. In older and co-operative children, grading of facial function using the House-Brackmann (H.B.) scoring system should be performed to assess the severity of FNP to allow assessment of recovery or progression at future visits.
6. Please make a note of the grade of palsy as it can be very helpful during follow up (see “Facial Nerve Grading Scale” below).

Clinical Guideline for Acquired Facial Nerve Palsy in Children (Bell's Palsy)

7. Examination of pinna, external auditory canals, tympanic membranes and oral cavity/oropharynx should be undertaken. Look for skin lesions or blisters on the face or in the ear canal as the presence of vesicles is suggestive of Ramsay–Hunt syndrome.
8. Signs of acute otitis media, acute mastoiditis and chronic otitis media with or without cholesteatoma should be looked for.
9. Stigmata of a temporal bone fracture should be sought in the presence of history of trauma (Battle's sign, haemotympanum and traumatic perforation).
10. Examination of eye should be performed by looking for degree of eyelid closure, redness of conjunctiva, frequency of blinking and excessive watering or dryness of the involved eye.
11. Examine the neck to look out for any lymph nodes or masses.
12. Joints should be examined where there is suspicion of Lyme disease (bilateral FNP with other cranial nerve involvement, due to *Borrelia spirochete*).

Facial Nerve Grading Scale	
Grade	Definition
I	Normal facial functions in all areas
II	Slight weakness noticeable only on close inspection Complete eye closure with minimal effort Slight asymmetry of smile with maximal effort No synkinesis, contracture of Hemifacial spasm
III	Obvious weakness, but not disfiguring May not be able to lift eyebrow Complete eye closure and strong but asymmetrical mouth movement with maximal effort Obvious, but not disfiguring synkinesis, mass movement or spasm
IV	Obvious disfiguring weakness Inability to lift brow Incomplete eye closure with asymmetry of mouth with maximal effort Severe synkinesis, mass movement, spasm
V	Motion barely perceptible Incomplete eye closure, slight movement of corner of mouth Synkinesis, contracture and spasm usually absent
VI	No movement, loss of tone, no synkinesis, contracture, or spasm

Investigations:

- Blood pressure should be verified in all cases of paediatric facial nerve paralysis. Facial nerve palsy can rarely be a complication and presenting feature of malignant hypertension.
- Consider doing a FBC and film to exclude Leukemia. (FNP as a presenting feature of Leukemia is extremely rare, but should be suspected in cases based on clinical examination).
- The lumbar puncture is performed only when suspecting meningitis (severe headache, fever, papilledema, neck stiffness) or Guillain-Barré syndrome.

Clinical Guideline for Acquired Facial Nerve Palsy in Children (Bell's Palsy)

- Specific laboratory and imaging tests are not routinely indicated, but are recommended for:
 - ✓ Patients with recurrent paralysis.
 - ✓ Or when there has been no improvement after 3 weeks with or without therapy.
 - ✓ Or complexity of symptoms not entirely in keeping with Bell's palsy.
- An ELISA serum searching for IgM and IgG antibody titer against Herpes Varicella-Zoster is recommended [9] if there is suspicion of Ramsay Hunt disease. Serologic tests for Lyme disease should be carried out when the history of the patient suggests a possible exposure.
- Hearing test- Audiometry and tympanometry should be performed if middle ear involvement is suspected
- Electrophysiological studies (NCV) can be useful to identify the cause of the paralysis, to define the prognosis and follow-up of functional recovery, but they are still not considered necessary in all paediatric patients [8-13].

Management

Main aims are to speed recovery and to prevent corneal complications.

Eye care – to protect the cornea from drying and abrasion.

- Frequent use of artificial tears during the day (e.g Hypromellose 0.3% eye drops) 6 times a day during day time
- Eye ointment (e.g Lacri-Lube) to lubricate the eye overnight
- Referral to eye clinic for examination/advice if there is no eye closure/red/painful eye.

Corticosteroids

- There is moderate- to high-quality evidence from randomised controlled trials showing significant benefit from treating Bell's palsy with corticosteroids in adults. (Cochrane review July 2016) [14].
- In children, although there is a limitation of data for lack of randomised controlled trials, but the use of oral corticosteroids is recommended preferably within 3 d (up to 7 days at the latest) from onset of symptoms [15].
- Start oral Prednisolone 1mg/kg/day (maximum dose 50 mg) for a week, and then stop.
- Recovery has been shown to be better with early treatment.
- Caution should be used in patients with diabetes mellitus, hypertension, renal or hepatic dysfunction or underlying immunocompromised state (seek specialist advice).

Antiviral agents

- When Bell's palsy occurs in adults, glucocorticoids in combination with antiviral therapy (acyclovir or valacyclovir) are recommended [16-19]. This combination

Clinical Guideline for Acquired Facial Nerve Palsy in Children (Bell's Palsy)

has proved to be superior than corticosteroids alone, especially in cases of severe palsy (grades 5 and 6) (Cochrane review Nov 2015).

- There is little evidence for the use of antivirals in the absence of any vesicles in children.
- However, The Ramsay Hunt syndrome should be treated as soon as possible with intravenous steroid along with antivirals in children older than 2 years in order to obtain a full recovery (in up to 75% of cases if treated within the first three days from onset) [4,20,21].

Follow up

- The patients with a diagnosis of Bell's palsy don't need specialized paediatric follow up and a GP follow up should suffice. Suggested time for monitoring recovery is 3 weeks, 3 months, 6 months and 1 year from onset. Please advise parents to take a picture/video of the face for records. An open access to CAU for up to 2 weeks may be useful and parents should be advised to ring CAU if there are concerns.
- If there is worsening of symptoms beyond 3 weeks, the child should be referred back to paediatrics urgently. Any evolving neurological signs at any time warrant an urgent review by a paediatrician.
- If symptoms have not started improving at 3 months or if they persist by 6 months, the child should be referred to Paediatric Neurology.
- Please give a copy of patient information leaflet from appendices.
- Please copy and paste the content of following box to the discharge letter as an advice to GP.

Dear GP,

.....(**insert name**) attended the children's department at NNUH and has been diagnosed with Bell's palsy with grade Weakness (HB score). He/She has been given a course of oral prednisolone (**Delete if not eligible**) and advised around eye care.

- We would be grateful if you could follow him/her up at 3 weeks, 3 months and further at 6 months and 1 year since onset of symptoms. (As clinically indicated).
- Please refer the child back urgently to CAU if symptoms are worsening beyond 3 weeks, or any time (even before 3 weeks) if there are evolving neurological symptoms.
- Please could you make a referral to Paediatric Neurology if there is no improvement at 3 months or persistent symptoms at 6 months?

Prognosis and Guidance for Parents

- Reassurance – most cases resolve spontaneously.

Clinical Guideline for Acquired Facial Nerve Palsy in Children (Bell's Palsy)

- Prognosis - 85% recover spontaneously with no residual facial weakness. 10% have mild facial weakness at 6 months and 5% will be left with permanent facial weakness.
- The degree of paralysis represents a prognostic element: patients with partial paralysis at onset have a better prognosis. Patients with grade II weakness (House- Brackmann scale) have a good outcome, while the III and the IV degrees are associated with moderate residual dysfunctions. The V and the VI degrees have poor prognosis of recovery [22,23]. Also, early response within first 3 weeks is a good prognostic indicator.
- Course - Maximal weakness at 3-7 days after onset, most cases improve within 3 weeks even without treatment, additional improvement may require up to 6 months. (No recovery within 3 weeks is associated with a worse prognosis).
- Complications - Corneal ulceration, permanent eyelid weakness, permanent facial asymmetry.

Surgical therapy

- In the paediatric population, the surgical decompression of the facial nerve in its labyrinthine segment is not recommended [2,7], primarily due to the lack of systematic clinical studies demonstrating its real effectiveness and secondly due to the risk of sensorineural hearing loss occurrence.
- In children presenting a permanent congenital or acquired facial palsy, surgical techniques of dynamic facial reanimation can be considered in order to tentatively restore a static and dynamic facial symmetry.

Others

- There is not enough evidence to recommend acupuncture and electrical nerve stimulation to accelerate healing by stimulating nerve/muscle. [10, 16,24-26].

Scope

This document is to be used to manage cases of acquired facial nerve palsy in paediatric population.

Clinical audit standards / audit standards / monitoring compliance

To ensure that this document is compliant with the above standards, the following monitoring processes will be undertaken:

- 1) Did children fulfilling the criteria receive the corticosteroids?
- 2) Was a proper follow up arranged with GP and clearly documented in discharge letter?
- 3) Were parents given an information leaflet?

Summary of development and consultation process undertaken before registration and dissemination

Clinical Guideline for Acquired Facial Nerve Palsy in Children (Bell's Palsy)

Dr V Kalra drafted this guideline on behalf of Dr Ruchi Arora, consultant paediatrician who has agreed the final content. It will be further reviewed in 2019.
This version has been endorsed by the department of Paediatrics and Paediatric Ophthalmology.

References

- 1 **Özkale Y**, Erol İ, Saygı S, Yılmaz İ. Overview of pediatric peripheral facial nerve paralysis: analysis of 40 patients. *J Child Neurol* 2015; **30**: 193-199
- 2 **Barr JS**, Katz KA, Hazen A. Surgical management of facial nerve paralysis in the pediatric population. *J Pediatr Surg* 2011; **46**: 2168-2176
- 3 **Lunan R**, Nagarajan L. Bell's palsy: a guideline proposal following a review of practice. *J Paediatr Child Health* 2008; **44**: 219-220
- 4 **Tiemstra JD**, Khatkhate N. Bell's palsy: diagnosis and management. *Am Fam Physician* 2007; **76**: 997-1002
- 5 **Stew B**, Williams H. Modern management of facial palsy: a review of current literature. *Br J Gen Pract* 2013; **63**: 109-110
- 6 **Shargorodsky J**, Lin HW, Gopen Q. Facial nerve palsy in the pediatric population. *Clin Pediatr (Phila)* 2010; **49**: 411-417
- 7 **Pavlou E**, Gkampeta A, Arampatzi M. Facial nerve palsy in childhood. *Brain Dev* 2011; **33**: 644-650
- 8 **Zieliński R**, Kobos J, Zakrzewska A. Parotid gland tumors in children - pre- and postoperative diagnostic difficulties. *Pol J Pathol* 2014; **65**: 130-134
- 9 **Derin S**, Derin H, Sahan M, Caksen H. A pediatric case of ramsay hunt syndrome. *Case Rep Otolaryngol* 2014; **2014**: 469565
- 10 **Finsterer J**. Management of peripheral facial nerve palsy. *Eur Arch Otorhinolaryngol* 2008; **265**: 743-752
- 11 **Kang HM**, Kim MG, Hong SM, Lee HY, Kim TH, Yeo SG. Comparison of temporal bone fractures in children and adults. *Acta Otolaryngol* 2013; **133**: 469-474
- 12 **Tsai HS**, Chang LY, Lu CY, Lee PI, Chen JM, Lee CY, Huang LM. Epidemiology and treatment of Bell's palsy in children in northern Taiwan. *J Microbiol Immunol Infect* 2009; **42**: 351-356
- 13 **Dushyant B**. Management of facial nerve palsy in newborn period. UK: Nottingham Neonatal Service-Clinical Guidelines (No. F16), 2013
- 14 **Madhok Vishnu B**, Corticosteroids for Bell's palsy (idiopathic facial paralysis) Cochrane Review July 2016
- 15 **Pitaro J**, Waissbluth S, Daniel SJ. Do children with Bell's palsy benefit from steroid treatment? A systematic review. *Int J Pediatr Otorhinolaryngol* 2012; **76**: 921-926
- 16 **de Almeida JR**, Guyatt GH, Sud S, Dorion J, Hill MD, Kolber MR, Lea J, Reg SL, Somogyi BK, Westerberg BD, White C, Chen JM. Management of Bell palsy: clinical practice guideline. *CMAJ* 2014; **186**: 917-922

Clinical Guideline for Acquired Facial Nerve Palsy in Children (Bell's Palsy)

- 17 **Shahidullah M**, Haque A, Islam MR, Rizvi AN, Sultana N, Mia BA, Hussain MA. Comparative study between combination of famciclovir and prednisolone with prednisolone alone in acute Bell's palsy. *Mymensingh Med J* 2011; **20**: 605-613
- 18 **Goudakos JK**, Markou KD. Corticosteroids vs corticosteroids plus antiviral agents in the treatment of Bell palsy: a systematic review and meta-analysis. *Arch Otolaryngol Head Neck Surg* 2009; **135**: 558-564
- 19 **Numthavaj P**, Thakkinstian A, Dejthevaporn C, Attia J. Corticosteroid and antiviral therapy for Bell's palsy: a network meta-analysis. *BMC Neurol* 2011; **11**: 1
- 20 **Clark GD**, Nordli DR, Dashe JF. Facial nerve palsy in children. Wolters Kluwer UpToDate® 2014. Available from: URL: <http://www.uptodate.com/contents/facial-nerve-palsy-in-children>
- 21 **Kansu L**, Yilmaz I. Herpes zoster oticus (Ramsay Hunt syndrome) in children: case report and literature review. *Int J Pediatr Otorhinolaryngol* 2012; **76**: 772-776
- 22 **Zandian A**, Osiro S, Hudson R, Ali IM, Matusz P, Tubbs SR, Loukas M. The neurologist's dilemma: a comprehensive clinical review of Bell's palsy, with emphasis on current management trends. *Med Sci Monit* 2014; **20**: 83-90
- 23 **Biebl A**, Lechner E, Hroncek K, Preisinger A, Eisenkölbl A, Schmitt K, Furthner D. Facial nerve paralysis in children: is it as benign as supposed? *Pediatr Neurol* 2013; **49**: 178-181
- 24 **Terzis JK**, Karypidis D. Therapeutic strategies in post-facial paralysis synkinesis in pediatric patients. *J Plast Reconstr Aesthet Surg* 2012; **65**: 1009-1018
- 25 **Pourmomeny AA**, Asadi S. Management of synkinesis and asymmetry in facial nerve palsy: a review article. *Iran J Otorhinolaryngol* 2014; **26**: 251-256
- 26 **McCaul JA**, Cascarini L, Godden D, Coombes D, Brennan PA, Kerawala CJ. Evidence based management of Bell's palsy. *Br J Oral Maxillofac Surg* 2014; **52**: 387-391
27. **Gagyar I et al**, Antiviral treatment for Bell's palsy (idiopathic facial paralysis); Cochrane review, published Nov 2015.

Clinical Guideline for Acquired Facial Nerve Palsy in Children (Bell's Palsy)

Appendix A

Bell's Palsy in Children: Patient Information Leaflet

[Trustdocs ID 14484](#)