

Trust Guideline for the Management of Hirschsprung's Disease in Neonates

A Clinical Guideline recommended

For Use in:	Neonatal Intensive Care Unit
By:	Neonatal and Paediatric medical, surgical and nursing staff
For:	Neonates and infants admitted to NICU
Division responsible for document:	Women and Children
Key words:	Hirschsprung's disease, aganglionosis, enterocolitis, colostomy, washout, paediatric surgery
Name and title of document author:	Mr Richard England, Consultant Paediatric Surgeon Mr Ashish Minocha, Consultant Paediatric Surgeon Mr Lee Smith, Specialist Registrar in Paediatric Surgery Mrs Billie Dean, Paediatric Nurse Specialist
Name and job title of document author's Line Manager:	Priya Muthukumar, Clinical Director
Supported by:	All Neonatologists, Paediatric / Neonatal Surgeons and Paediatric Gastroenterologists (Dr R Roy, Dr P Clarke, Dr M Dyke, Dr D Booth, Dr P Muthukumar, Dr F Walston, Mr M S Kulkarni, Mr A B Mathur, Mr A Minocha,
Assessed and approved by the:	Clinical Guidelines Assessment Panel (CGAP) If approved by committee or Governance Lead Chair's Action; tick here <input checked="" type="checkbox"/>
Date of approval:	13/07/2022
Ratified by or reported as approved to (if applicable):	Clinical Safety and Effectiveness Sub-Board
To be reviewed before: This document remains current after this date but will be under review	13/07/2025
To be reviewed by:	Mr Richard England, Mr Ashish Minocha,
Reference and / or Trust Docs ID No:	12489
Version No:	4
Compliance links: (is there any NICE related to guidance)	None
If Yes - does the strategy/policy deviate from the recommendations of NICE? If so why?	Not applicable.

This guideline has been approved by the Trust's Clinical Guidelines Assessment Panel as an aid to the diagnosis and management of relevant patients and clinical circumstances. Not every patient or situation fits neatly into a standard guideline scenario and the guideline must be interpreted and applied in practice in the light of prevailing clinical circumstances, the diagnostic and treatment options available and the professional judgement, knowledge and expertise of relevant clinicians. It is advised that the rationale for any departure from relevant guidance should be documented in the patient's case notes.

The Trust's guidelines are made publicly available as part of the collective endeavour to continuously improve the quality of healthcare through sharing medical experience and knowledge. The Trust accepts no responsibility for any misunderstanding or misapplication of this document.

Trust Guideline for the Management of Hirschsprung's Disease in Neonates

Version and Document Control:

Version Number	Date of Update	Change Description	Author
4	May 2022	Washout, enterocolitis and care of the family additions	Richard England

This is a Controlled Document

Printed copies of this document may not be up to date. Please check the hospital intranet for the latest version and destroy all previous versions.

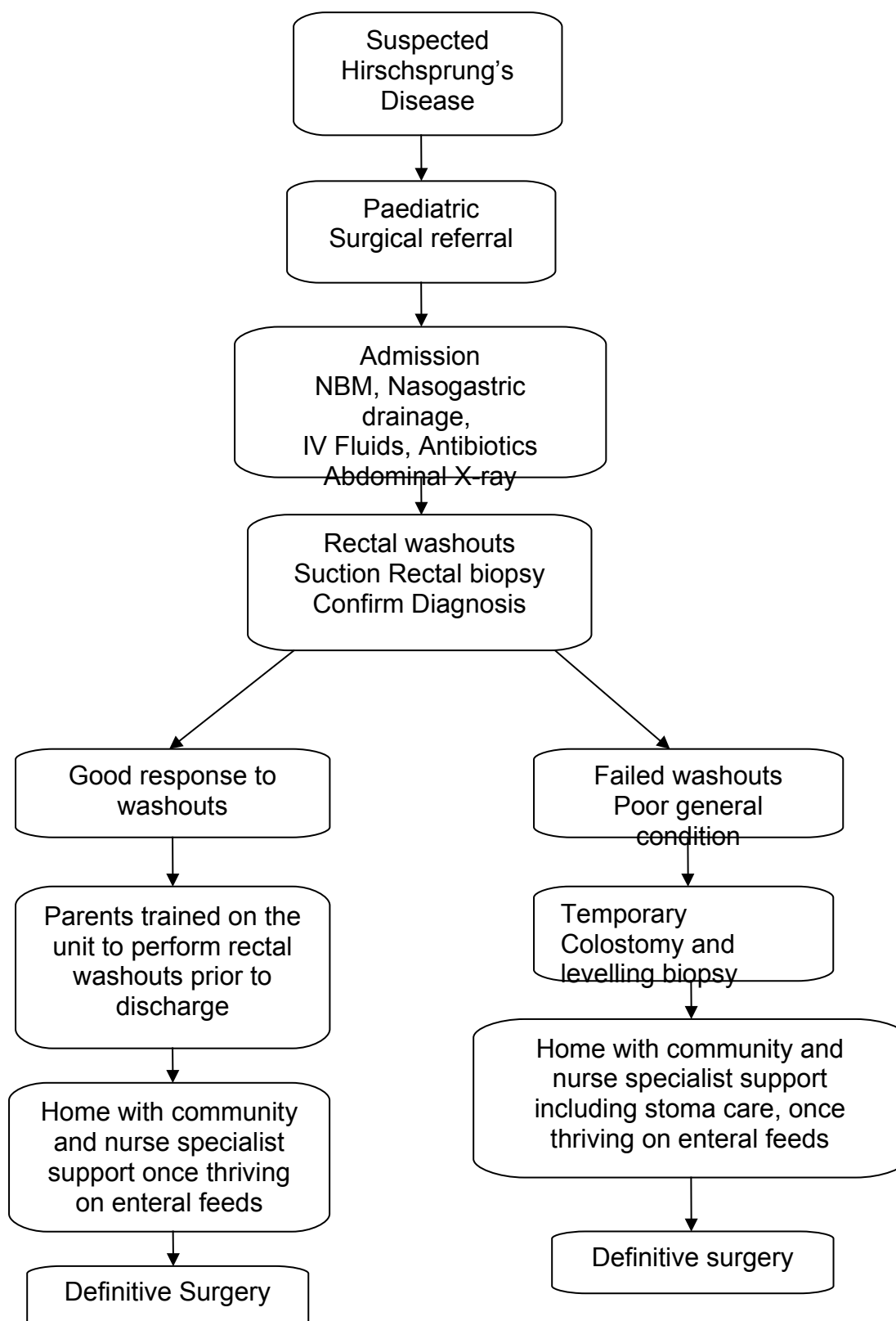
Trust Guideline for the Management of Hirschsprung's Disease in Neonates

Contents

1. Quick reference flowchart	4
2. Objectives	5
3. Rationale	5
4. Definition of terms used	5
5. Introduction	6
6. Diagnosis	6
7. Antenatal diagnosis	6
8. Postnatal diagnosis	7
9. Initial management	7
10. Surgical management in the newborn period	8
11. Associated abnormalities	9
12. Enterocolitis	9
13. Care of the family	10
14. Subsequent neonatal management	10
15. Planning for discharge and follow-up arrangements	11
16. Summary of further management and outcome	12
17. Clinical audit standards / monitoring compliance	12
18. Summary of development and consultation process	13
19. Distribution list	13
20. References	13
21. Figures	14
22. Appendix 1: Length of bowel involved	17
23. Appendix 2: Suction rectal biopsy equipment list	18
24. Appendix 3: Syndromes associated with HD	19
25. Appendix 4: Enterocolitis Medical Alert card	20
26. Appendix 5: Monitoring compliance and effectiveness table	21

Trust Guideline for the Management of Hirschsprung's Disease in Neonates

Quick reference flowchart



Trust Guideline for the Management of Hirschsprung's Disease in Neonates

Objectives

Ensure best practice in the diagnosis, investigation and management of a baby born with Hirschsprung's Disease (HD) in the newborn period.

Rationale

This guideline has been written to ensure that all babies born with Hirschsprung's Disease are diagnosed in a timely manner and managed appropriately to avoid complications. This guideline will also help medical and nursing staff explain the management clearly to parents. Most of the recommendations are derived from standard national practice in paediatric surgery and published literature.

Definitions of Terms Used

Aganglionosis / aganglionic: Implies absence of ganglion cells or nerve cells.

Hirschsprung's Disease: Condition involving aganglionic (dysfunctional / aperistaltic) segment of bowel resulting in functional intestinal obstruction. (Fig 1) Depending on the level of aganglionosis HD is classified into different types (Appendix 1). Hirschsprung's disease is caused when certain nerve cells (called parasympathetic ganglion cells) in the wall of the large intestine (colon) do not develop. Without these nerve cells, the affected segment of the colon lacks the ability to relax and move bowel contents along. This causes a constriction and as a result, the bowel above the constricted area dilates due to stool becoming trapped, producing megacolon (dilatation of the colon). The disease can affect varying lengths of bowel segment, most often involving the region around the rectum. In up to 10% of children with Hirschsprung's the entire colon and part of the small intestine are involved. This condition is known as total colonic aganglionosis, or TCA.

Colostomy: Opening of the bowel (usually sigmoid colon) onto the skin to divert faeces away from the perineum.

Enterocolitis: Inflammation of the colon. Maybe infective in origin but can be more aggressive in nature than normal gastroenteritis. Children with HD are more prone to enterocolitis in particular those who also have Down's Syndrome.

Ganglion cell: This cell is part of the enteric nervous system. Absence of ganglion cells is the hallmark of Hirschsprung's Disease.

Rectal biopsy: This is a procedure to obtain a tiny piece of rectal wall for histology. A suction rectal biopsy (partial thickness) can be performed at the bedside on the unit. (Fig. 2) In some cases a full thickness biopsy is performed in theatres under general anaesthesia.

'Pull through' Surgery: This term is used to explain the definitive operation in the management of HD. It involves 'pulling down' the proximal ganglionic (normal functioning / peristaltic) bowel to the anal opening. There are 2 main types of pull through used in this unit; the Duhamel Procedure and the Soave procedure (Fig 3).¹⁻²

Trust Guideline for the Management of Hirschsprung's Disease in Neonates

Introduction

Hirschsprung's disease (HD) is a disorder of the migration of the neural crest cells to the enteric nervous system resulting in congenital aganglionosis of the distal bowel. Harold Hirschsprung, a Danish pediatrician presented the most telling and concise description of congenital megacolon in 1886.

HD is seen in approximately 1 in 5000 live births. The overall male:female ratio is 3:1 to 4:1 however when the whole colon is involved the gender ratio is 1:1.

Hirschsprung's Disease involves aganglionic (dysfunctional / aperistaltic) segment of bowel resulting in functional intestinal obstruction. It commonly presents during the neonatal period with a triad of delayed passage of meconium, abdominal distension and bilious vomiting. Some newborns may present with sepsis from enterocolitis. Late presentation in childhood varies from chronic constipation, abdominal distension, failure to thrive or recurrent enterocolitis.

Treatment requires complex surgery to remove the aganglionic segment and take the ganglionic segment down to the anal opening. Depending on the clinical presentation and level of aganglionosis child may require a single or staged procedure. The process of managing this condition starts with recognition and correct diagnosis. Delayed recognition can lead to complications and distress for the baby and parents.

Specialised investigations may be needed at different stages of the management before definitive surgery can be undertaken.

Rectal wash outs may be initiated by the surgical team to help decompress the bowel. If rectal washouts are not possible or fail to adequately remove the stool the baby will need a colostomy. The neonatal and surgical team will be able to prepare the baby and family for this and train the parents in the management of the colostomy while waiting for the definitive surgery.

It is important to ensure the baby is otherwise developing well, putting on weight and feeding well. Routine neonatal checks and tests should continue as normal.

Diagnosis:

History and clinical presentation can suggest the presence of Hirschsprung's disease, however further investigations are required to confirm the diagnosis and determine the level of aganglionosis. A contrast enema may help the diagnosis, but histopathological diagnosis on biopsy is the gold standard. Biopsies can be obtained by a Suction Rectal Biopsy on the ward or intra-operatively depending on the general condition of the child.

Antenatal diagnosis

It is not possible to make a specific diagnosis of HD antenatally. Features suspicious of bowel obstruction, such as dilated loops of bowel, may be seen on antenatal scans. These should prompt referral to a Fetal Medicine Subspecialist. Differential diagnoses with significant generalised antenatal bowel dilatation include, anorectal malformations, and Cystic Fibrosis. Although syndromic associations with HD are relatively rare, genetic transmission is known and family history is important. However, prenatal genetic testing cannot accurately predict the

Trust Guideline for the Management of Hirschsprung's Disease in Neonates

diagnosis. Discussion with a paediatric surgeon with a view to counselling would be appropriate in cases of significant bowel dilatation.

Postnatal diagnosis

98% of normal full term babies will pass meconium in 24 - 48 hrs. Delay in passage of meconium should be documented by the healthcare professional looking after the baby (neonatologist or community midwife), and should raise the suspicion of HD. All babies with delayed passage of meconium should be referred for further assessment (Audit standard 2)

Neonates often present with abdominal distension, increased aspirates / bilious aspirates. Inflammation of the bowel can be due to enterocolitis, leading to sepsis. If this occurs the baby can be particularly unwell.

Less frequently children can have delayed presentation with feed intolerance, failure to open bowels spontaneously or failure to thrive.

Ideally all patients with Hirschsprung's disease would be identified within the neonatal period (Audit standard 1).

Initial management

All babies should have a complete neonatal examination and additional anomalies managed as appropriate.

If HD is suspected and there is significant abdominal distension, then feeds should be stopped. A large size nasogastric tube (8-10 Fr) is desirable in a full term normal size baby. Gastric placement should be confirmed. It should be left on free drainage and aspirated regularly. The interval between aspirations should be no greater than 4 hrly. Aspirates should be replaced ml for ml. Intravenous access should be obtained and blood tests for U&E, FBC, Blood culture, blood glucose and Group and Save taken. IV fluids should be initiated according to the unit policy.

A Paediatric Surgical referral should be made and their subsequent clinical assessment documented (Audit standard 3).

A decision when a long line and TPN is required can be taken jointly between the neonatal, paediatrics gastroenterology and surgical teams, as time to achieving adequate feeds varies depending on the level of aganglionosis and condition of the baby.

IV antibiotics including anaerobic cover should be given. The duration of cover is dictated by culture results and surgical management.

All babies should have received IV or IM Vitamin K, even if a dose of oral vitamin K has been given. Oral vitamin K is unreliably absorbed in bowel obstruction.

A plain abdominal X ray is advised in presence of distension.

Trust Guideline for the Management of Hirschsprung's Disease in Neonates

Surgical management in the newborn period

The surgical management is determined by the general condition of the child, level of aganglionosis and efficacy of rectal washouts in decompressing the bowels.

If the general condition is stable, rectal washouts are initiated using warm 0.9% sodium chloride using an Mcath4 catheter 10-12 Ch and bladder syringe.

Hegars dilators can be used for gentle rectal stimulation.

The surgical team or Paediatric Surgery Nurse Specialist will initiate the washouts and ensure the neonatal nursing staff are adequately trained to carry on with the washouts as advised. Rectal washouts and training of staff and parents should follow the guidance in [document 14486 Rectal Washouts for Babies with Hirschsprung's or Bowel Motility Disorders](#).

Approximate volume of fluid required can be up to 100-150 mLs/kg/washout. The endpoint is clear backflow (returning fluid). Washout is to be stopped if baby is unduly distressed, cold or unwell. Rectal washouts should be clearly documented detailing –

- 1) The time of washout
- 2) The total amount of sodium chloride used
- 3) Quantity and character of the returning fluid (Returning fluid should be approximately equal to the starting amount allowing for spillages that may have occurred)
- 4) Note any offensive smell, unusual colour or presence of blood
- 5) Note change in abdominal fullness / degree of decompression before and after the washout.

If washouts are difficult and do not adequately decompress the abdomen then the technique should be re-assessed by an experienced neonatal nurse / nurse specialist or surgeon. A larger tube (16 Fr) may be tried which is less likely to block or the frequency of washouts may need to be increased to 2-3 times per day for a period of time. Long segment or total colonic HD may be a cause of such difficulty and should be considered.

Once the baby's general condition permits, a 'suction rectal biopsy' is undertaken by using biopsy forceps which are inserted into the anus and a small piece of tissue (biopsy) is taken from the posterior rectal wall. This procedure is usually undertaken on the neonatal unit / paediatric ward and takes approximately 20-30 minutes – to obtain 3 adequate pieces of tissue. It is performed without any anaesthetic as it is only uncomfortable but not painful to the baby. Antibiotics are to be considered depending on child's general condition (if not already on them) and in general this is standard for patients on the neonatal unit. Following the procedure washouts are stopped for 24hrs. The baby is observed closely for rectal bleeding and sepsis. If bleeding occurs pressure should be applied per-rectum by the surgical team. Although rare, perforation is a known complication of the procedure and one should have a low threshold of suspicion if there is sudden abdominal distension or deterioration in the general condition.

The rectal biopsy should be documented in the notes. The histology results may take a few days or sometimes longer to come back. Once the results are available the surgeon can explain the diagnosis and plan to the parents. This conversation should be documented on the blue communication sheets (Audit standards 4-5).

Trust Guideline for the Management of Hirschsprung's Disease in Neonates

See Appendix 2 for a list of equipment required for the biopsy and there is an associated LocSSIP document to be completed. Rectal Biopsy for Suspected Hirschsprung's Disease – Paediatric and Neonatal Surgery (LocSSIP) [Trustdocs Id:14078](#)

A classical Hirschsprung's (Recto-sigmoid) segment (see Fig. 1) may be managed initially with rectal washouts. The child can be discharged home when parents are trained and are able to do the washouts. However there must be adequate Paediatric surgery nurse specialist and community nursing support for the parents and regular reviews arranged to ensure the washouts are being performed safely and effectively.

If the general condition of the child is poor or rectal washouts are ineffective an urgent colostomy may be required. This allows decompression of the bowels and biopsies are taken which confirm the level of aganglionosis to help plan the definitive procedure at a later date.

Associated abnormalities

Please refer to the table of associated genetic conditions in Appendix 3

- Family history is important (up to 3rd generation) and a family tree should be documented.
- Developmental disorders, growth abnormalities or multiple congenital anomalies should prompt an early clinical geneticist referral.

Every baby with a Hirschsprung's diagnosis should have a microarray genetic test (EDTA and lithium heparin sample). For those with long segment / Total Colonic Hirschsprung's, familial Hirschsprung's or a family history of thyroid disease or MEN (Multiple Endocrine Neoplasia) then RET mutation analysis should specifically be requested (sent in EDTA sample). These patients have a higher potential for MEN2A or B and may develop medullary thyroid cancer, in which case a prophylactic thyroidectomy may be considered.³⁻⁴

A renal ultrasound should be considered in all patients. Up to 20% of patients may have a urinary tract abnormality. Cardiac evaluation and echocardiogram should also be considered, especially in syndromic or long segment patients, as 5% can have cardiac defects (ASD /VSD).⁵

Enterocolitis

This is an aggressive inflammatory condition of the bowel which can affect babies and children with Hirschsprung's disease – either before or after pull through surgery. It presents with abdominal distension as well as lethargy, vomiting, diarrhoea or fever. Clinicians should have a high index of suspicion for this diagnosis and initiate early treatment if suspected as it can rapidly progress to a severe fulminant life-threatening state. Early presentation of parents to hospital with these symptoms should be encouraged and they must be educated about this condition before leaving hospital. They should be given 2 x Medical Alert Enterocolitis cards (see appendix 4) to carry with them at all times.

Immediate treatment is for the baby to be made nil by mouth, achieve IV access, give antibiotics including metronidazole and an IV fluid bolus to compensate for bowel fluid loss. A nasogastric tube may be needed especially if the baby is vomiting. A PR examination may allow immediate decompression of foul smelling watery stool and this can be further relieved by a thorough rectal washout. Repeated episodes of enterocolitis may necessitate a stoma formation.

Trust Guideline for the Management of Hirschsprung's Disease in Neonates

Care of the family

It is important at each stage of this presentation to update the family and explain the treatment in progress. Washouts and rectal interventions on a newborn baby can appear distressing and messy to the family and so reassurance is necessary, with the observation that the abdomen becomes less distended and the baby may feed better.

Once the diagnosis of Hirschsprung's disease is made then a comprehensive discussion with the parents should be held – with, if possible, a consultant experienced in paediatric colorectal surgery who would take over the long-term care of the child. The paediatric surgery nurse specialist should also be present if possible and meet with the family during the admission to form a working relationship and answer any further questions.

The neonatal unit has a clinical psychologist and once the family have received this life changing diagnosis for their baby, they should be offered an appointment with the clinical psychologist to help them process the information and talk through how they will adapt to managing their baby's condition.

The family care team on NICU will be involved in planning discharge and help with any further social / community / financial support that may be available.

Parents often have questions about their other children and genetic studies may be helpful in answering questions for their other children or future offspring. A member of the team trained in genetic testing consent may be able to request further tests or the family can be referred to the clinical genetics teams.

Subsequent neonatal management

Babies who respond well to rectal washouts go home once parents are trained for washouts and community support is arranged. They are followed in the surgical clinic to assess growth and make plans for primary pull-through.

Babies who need a colostomy in the neonatal period should have IV fluids for maintenance hydration unless they have already been started on TPN. Feeds can be started according to the surgeon's instructions.

If a colostomy has been performed it should be kept moist and loosely covered until it starts to work. The paediatric surgery nurse specialist should be asked to review and discuss stoma care with the parents (Audit standard 6). Stoma bag can be applied once the stoma starts to work unless there are conflicting wound care issues.

The baby can go home once parents are trained to manage the stoma. They are followed in the surgical clinic to assess growth and make plans for the definitive pull-through at a later date.

Planning for discharge and follow-up arrangements

1. Specific follow-up arrangements depend on the individual patient and the type / level of Hirschsprung's Disease.

Trust Guideline for the Management of Hirschsprung's Disease in Neonates

2. The parents will be fully competent at bowel washouts or stoma care as appropriate.
3. The Paediatric Surgeon involved will arrange to see the baby in clinic.
4. Premature neonates or those with associated anomalies should also be reviewed by a neonatologist to ensure they are developing normally and to provide a medical review.
5. Baby's transferred from outside the Norwich area should be referred to their local paediatrician for regular follow-up and coordination of multi-disciplinary team involvement.
6. A neonatal outreach or community nurse should be informed and follow-up visits at home arranged.
7. If a stoma has been formed then the Paediatric Surgery Nurse Specialist will liaise with the family or community stoma nurse who can visit the family at home to assess ongoing needs. Stoma care supplies should be arranged and troubleshooting information given for problems such as prolapse and bag leakage. The PSNS and community nurses should ensure the parents can recognise that high output from the stoma may need medical attention.
8. Parents need to be discharged with enough supplies for bowel washouts or stoma care and ordering / delivery requests for further supplies and prescriptions should be in place.
9. The General Practitioner should receive a copy of the neonatal discharge letter.
10. Parents should receive a copy of the discharge letter or other documentation explaining the diagnosis and follow-up arrangements.
11. Parents should receive two copies of the enterocolitis medical alert card.
12. Parents will have been given the opportunity to have psychology support for this life changing diagnosis.
13. Open access to Children's Assessment Unit (JLCH) or their local paediatric unit must be arranged - with no end date.
14. The complex paediatric surgery PAS alert must be applied.

Summary of further management and outcome

Patients who have had a primary pull through may need no further surgery but will be followed up by the paediatric surgeon. Any constipation or soiling will be monitored by them and advice on laxative use will be given.

Trust Guideline for the Management of Hirschsprung's Disease in Neonates

A patient who has received an initial colostomy will be allowed to grow and develop for a number of months before definitive surgery (pull through operation) is planned. They may undergo further investigations within this period to assess and plan the definitive surgery.

Once the definitive surgery is performed paediatric surgeons will instruct parents if they require anal dilatations to be performed. A stoma may or may not be present following the pull through operation. If there is a stoma then the surgeon will decide how soon this can be closed.

The outcome for Hirschsprung's Disease is generally good however the quality of life is very dependent on the level of aganglionosis. The paediatric surgeon will discuss issues such as constipation, soiling and incontinence with the parents. Syndromic associations (e.g. Trisomy 21) may influence the overall progress of the patient.

Clinical audit standards / monitoring compliance

To ensure that care is compliant with the above standards, the following monitoring processes will be undertaken:

Planned audit of this guideline should be carried out at regular intervals (suggested 3-5 yearly intervals).

Suggested criteria are as follows but can be modified according to perceived needs at the time of audit.

- 1) Diagnosis of Hirschsprung's Disease within the neonatal period, ideally prior to discharge
- 2) All patients diagnosed with Hirschsprung's disease should have had time of passage of meconium documented by a health care professional.
- 3) Documentation of clinical examination by surgeon
- 4) Documentation of investigations e.g. biopsy results
- 5) Documentation of at least one discussion with parents concerning the diagnosis and subsequent plan of treatment by the surgical team.
- 6) Involvement of a stoma nurse or paediatric surgery nurse specialist should be documented in all cases.

The audit results will be discussed in the Paediatric Surgery GI MDT and included in the minutes. They should also be submitted to the Paediatric surgery audit lead or clinical governance lead who will ensure that these are discussed at relevant governance meetings to review the results and make recommendations for further action.

Summary of development and consultation process undertaken before registration and dissemination

The authors listed above drafted the guideline. During its development it was discussed at a multidisciplinary guideline meeting of the Paediatric Surgical Department and the Neonatal Unit, changes suggested were discussed and incorporated. It was subsequently circulated for comment to the Paediatric Medicine and Surgical Departments and the Neonatal Unit

Trust Guideline for the Management of Hirschsprung's Disease in Neonates

(Consultants, Specialist Registrars, Advanced Neonatal Nurse Practitioners, Sisters and Senior Staff Nurses. In addition, the draft guideline was forwarded to the fetomaternal medicine department, paediatric radiologists and stoma nurses. Suggestions for further improvement were incorporated; consensus was reached for non-evidence based treatment (advised according to current expert opinion/best practice).

This version has been endorsed by the Clinical Guideline Assessment Committee.

Distribution list/ dissemination method

Neonatal Unit / NNUH Intranet clinical guidelines

References

1. Bradnock TJ, Walker GM. Evolution in the management of Hirschsprung's disease in the UK and Ireland: a national survey of practice revisited. *Ann R Coll Surg Engl* 2011; 93: 34-38
2. Keckler, SJ, Yang JC, Fraser JD, et al. Contemporary practice patterns in the surgical management of Hirschsprung's disease. *J Pediatr Surg* 2009; 44:1257-1260
3. Amiel J, Sproat-Emison E, Garcia-Barcelo M, et al. Hirschsprung disease, associated syndromes and genetics: a review.
4. *J Med Genet* 2008; 45:1-14
4. Coyle D, Friedmacher F, Puri P. The association between Hirschsprung's disease and multiple endocrine neoplasia type 2a: a systematic review. *Pediatr Surg Int* 2014; 30:751-6
5. Prato AP, Rossi V, Mosconi M, et al. A prospective observational study of associated anomalies in Hirschsprung's disease. *Orphanet J Rare Dis* 2013; 8:184-196

Trust Guideline for the Management of Hirschsprung's Disease in Neonates

Fig 1. Hirschsprung's Disease: Demonstrates the common distribution of a constricted aganglionic rectosigmoid colon and proximal dilated ganglionic descending colon.

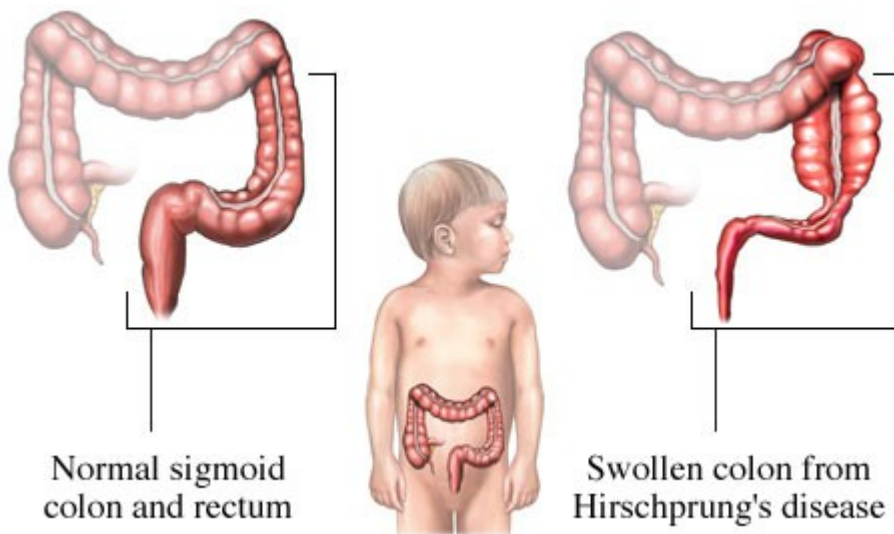
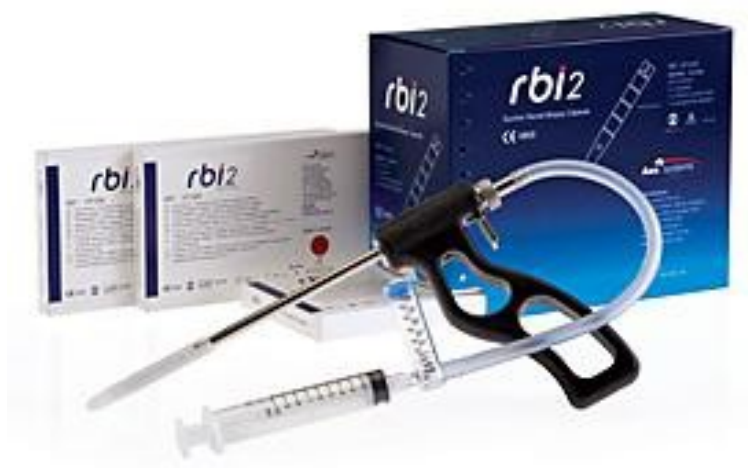

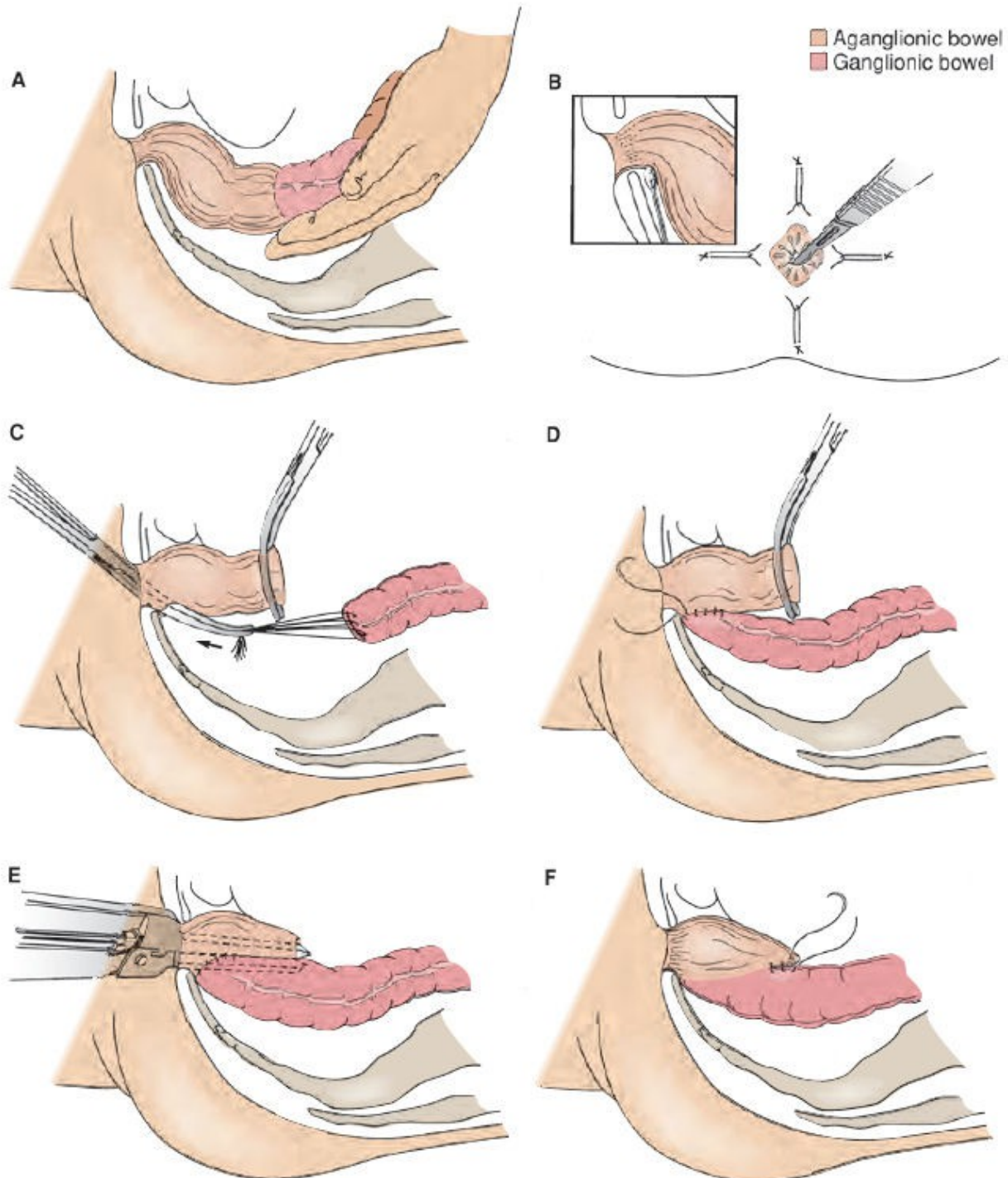
Fig 2. Rectal Suction Biopsy: The rectal suction biopsy apparatus applies a small amount of suction to the rectal wall before taking a tiny piece of mucosal lining for histology.



See appendix 2 for List of equipment required for performing a suction rectal biopsy

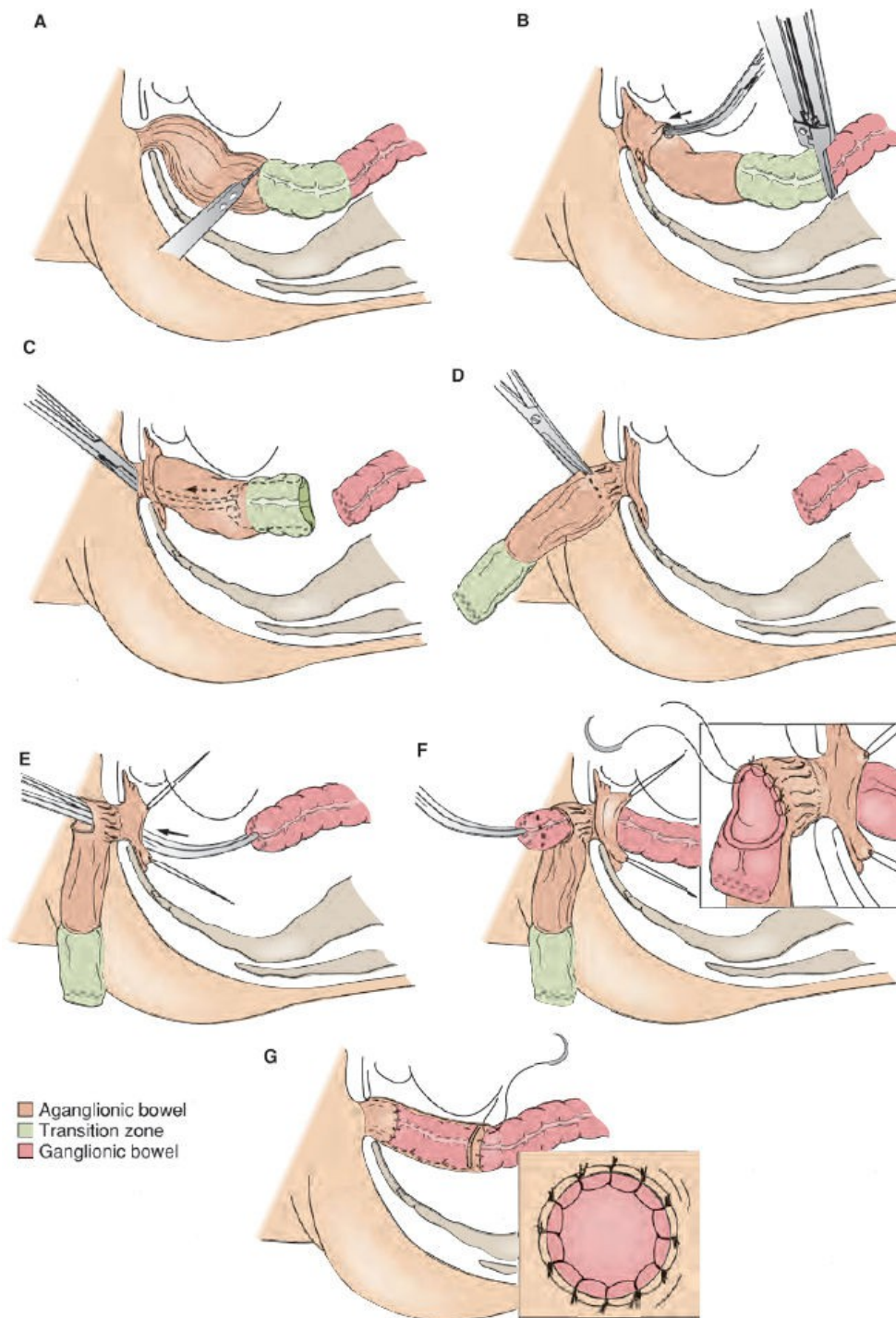
Fig 3. Pull through Procedures

a) Duhamel procedure



Trust Guideline for the Management of Hirschsprung's Disease in Neonates

b) Soave procedure



Trust Guideline for the Management of Hirschsprung's Disease in Neonates

Appendix 1

Length of Bowel Involved	Proportion of HD cases
Rectosigmoid	70-80%
Long segment (above sigmoid)	10-25%
Total Colonic	3-15%
Total Intestinal	0.4-4%
Ultrashort segment	<1%

Trust Guideline for the Management of Hirschsprung's Disease in Neonates

Appendix 2

Suction Rectal Biopsy equipment list

Consent for completed

Histopathology department informed

Assistant and nurse available

In neonates not already on broad spectrum antibiotics, a dose of IV Cefotaxime and Metronidazole (7.5mg/kg) should be given.

rbi 2 Biopsy gun and 2 packets of cartridges

3 formalin specimen pots

10mL syringe x3 and 20mL syringe x1

Green needle

10mL vials x 4 of 0.9% sodium chloride

Inco pads

Gauze swabs

K-Y jelly

Remember to complete the Rectal Biopsy LocSSIP- Rectal Biopsy for Suspected Hirschsprung's Disease – Paediatric and Neonatal Surgery (LocSSIP) [Trustdocs Id:14078](#)

Trust Guideline for the Management of Hirschsprung's Disease in Neonates

Appendix 3

Syndromes associated with HD²

	Syndromes	Key features
Syndromic Neural Crest Cells disorders	Shah-Waardenburg	Pigmentary anomalies (white forelock, iris hypoplasia, patchy hypopigmentation)
	Yemenite deaf-blind-hypopigmentation	Hearing loss, eye anomalies (microcornea, coloboma, nystagmus), pigmentary anomalies
	BADS	Hearing loss, hypopigmentation of the skin and retina*
	Piebaldism	Patchy hypopigmentation of the skin
	Haddad	Congenital central hypoventilation
	MEN2A	Medullary thyroid carcinoma, pheochromocytoma, hyperplasia of the parathyroid
	Riley – Day	Autonomic nervous system anomalies
HD mandatory	Goldberg-Shprintzen	Mental retardation, polymicrogyria, microcephaly, CF, coloboma, facial dysmorphic features
	HD with limb anomalies	Polydactyly, unilateral renal agenesis, hypertelorism, deafness
		Postaxial polydactyly, ventricular septal defect
		Hypoplasia of distal phalanges and nails, dysmorphic features
		Preaxial polydactyly, heart defect, laryngeal anomalies
		Brachydactyly type D
	BRESHEK	Brain abnormalities, Retardation, Ectodermal dysplasia, Skeletal malformation, Ear/eye anomalies, Kidney dysplasia
	Mowat-Wilson	Mental retardation, microcephaly, epilepsy, facial gestalt, hypospadias, renal anomalies
HD occasionally associated	Bardet-Biedl syndrome	Pigmentary retinopathy, obesity, hypogenitalism, mild mental retardation, postaxial polydactyly
	Kauffman-McKusick	Hydrometrocolpos, postaxial polydactyly, congenital heart defect
	Smith-Lemli-Opitz	Growth retardation, microcephaly, mental retardation, hypospadias, 2–3 toes syndactyly, dysmorphic features
	Cartilage-hair hypoplasia	Shortlimb dwarfism, metaphyseal dysplasia immunodeficiency
	HSAS/MASA	Hydrocephalus, aqueductal stenosis, spasticity adducted thumbs, ACC, mental retardation
Miscellaneous associations	Jeune asphyxiating thoracic dystrophy, Pallister-Hall (CAVE) Fryns, Aarskog, Fronto-nasal dysplasia, Osteopetrosis, Goldenhar Lesch-Nyhan, Rubinstein-Taybi, Toriello-Carey, SEMDJL	



Adapted from: Scriver CM et al. *The metabolic and molecular bases of inherited diseases*. 8th ed. McGraw-Hill, pp 6231-55. ³

Trust Guideline for the Management of Anorectal Malformation in Neonates and Infants

Appendix 4

Enterocolitis Medical alert card

These are kept with Mr England. Two copies are sent to each family.

	Medical Alert	 Norfolk and Norwich University Hospitals NHS Foundation Trust
This child has Hirschsprung's Disease and is at risk of Hirschsprung's Enterocolitis	<u>Immediate Treatment</u> Stop oral feeds, Triple IV Antibiotics, IV Fluid bolus, NG Tube and Rectal Washout	
Features New onset abdominal distension with: Lethargy, fever, vomiting or diarrhoea.	Please contact the on-call Paediatric Surgical Registrar at Jenny Lind Children's Hospital 01603 286286	

Trust Guideline for the Management of Hirschsprung's Disease in Neonates

Monitoring Compliance / Effectiveness Table

Document Name: Management of Hirschsprung's Disease in Neonates

Document Owner: Mr Richard England

Appendix 5

<i>Element to be monitored</i>	<i>Lead Responsible for monitoring</i>	<i>Monitoring Tool / Method of monitoring</i>	<i>Frequency of monitoring</i>	<i>Lead Responsible for developing action plan & acting on recommendations</i>	<i>Reporting arrangements</i>	<i>Sharing and disseminating lessons learned & recommended changes in practice as a result of monitoring compliance with this document</i>
Diagnosis of Hirschsprung's Disease within the neonatal period	R England	Audit	5yrs	R England	Paediatric Surgery and neonatal Governance meetings	<i>The Lead responsible for developing the action plans will disseminate lessons learned via the most appropriate committee e.g. Clinical Effectiveness; Clinical Governance, Patient Safety.</i>
All patients diagnosed with Hirschsprung's disease should have had time of passage of meconium documented by a health care professional.	R England	Audit	5yrs	R England	Paediatric Surgery and neonatal Governance meetings	
Documentation of clinical examination by surgeon	R England	Audit	5yrs	R England	Paediatric Surgery and neonatal Governance meetings	
Documentation of investigations e.g. biopsy results	R England	Audit	5yrs	R England	Paediatric Surgery and neonatal Governance meetings	
Documentation of at least one discussion with parents concerning the diagnosis and subsequent plan of treatment by the surgical team.	R England	Audit	5yrs	R England	Paediatric Surgery and neonatal Governance meetings	
Involvement of a stoma nurse or paediatric surgery nurse specialist should be documented in all cases.	R England	Audit	5yrs	R England	Paediatric Surgery and neonatal Governance meetings	